

WHAT IS X-LINKED HYPOPHOSPHATAEMIA (XLH)?

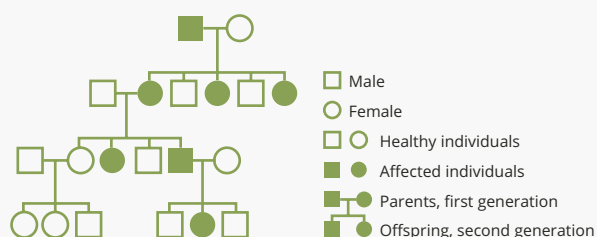
XLH is a rare, hereditary, chronic and progressive musculoskeletal disorder, resulting from excess FGF23 production¹⁻⁴



Prevalence

- XLH is estimated to affect approximately 1 in 20,000–1 in 60,000 people^{1,4,6}

PEDIGREE ANALYSIS



Inheritance

- XLH is inherited in an X-linked dominant pattern and is caused by a loss-of-function mutation in the PHEX gene.^{5,7,8}
 - However, in approximately 20–30% of cases XLH occurs spontaneously and there is no family history⁹⁻¹¹

XLH mechanism of disease



Mutations in the *PHEX* gene inherited in an X-linked pattern¹²

Increased expression of FGF23¹³



Renal phosphate wasting and low 1,25(OH)₂D¹³

Low levels of serum phosphate¹³

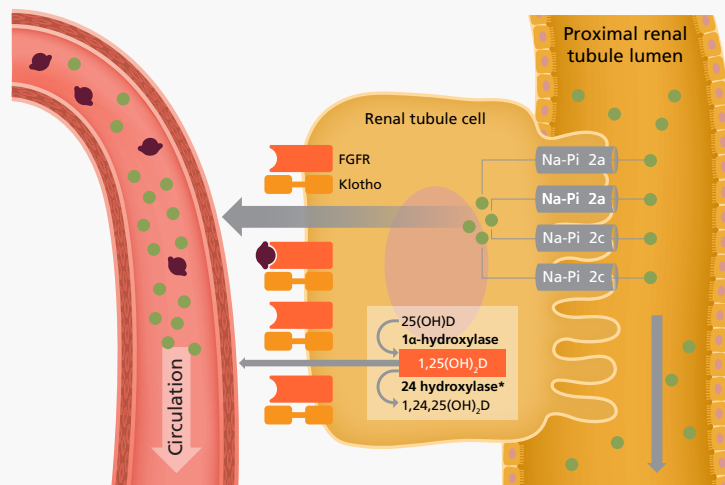


Clinical manifestations of XLH¹³

Role of FGF23

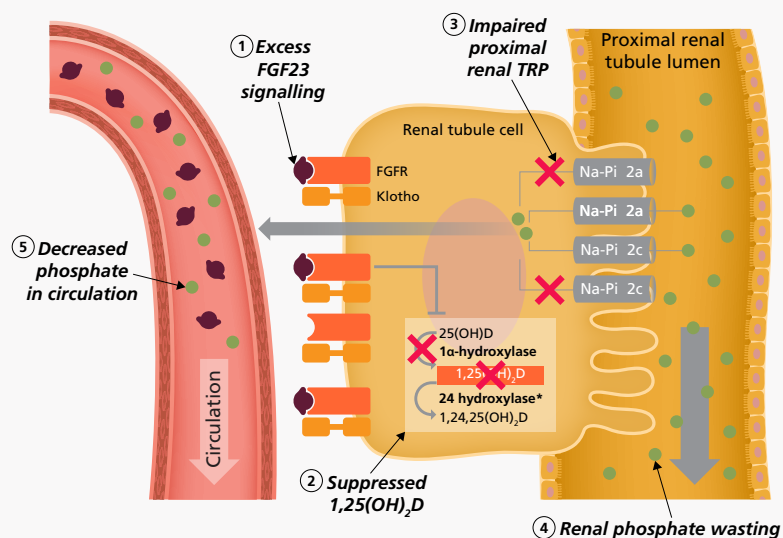
In XLH, excessive levels of FGF23 result in renal phosphate wasting and decreased active vitamin D levels, causing chronic hypophosphataemia^{2,3}

FGF23 in healthy individuals^{3,14-18}



- FGF23 is a bone-derived hormone that regulates phosphate metabolism,¹⁹ which is critical to lifelong skeletal health¹⁶
- FGF23 regulates serum phosphate levels by decreasing both phosphate reabsorption in the kidneys and 1,25(OH)₂D production, leading to decreased intestinal phosphate absorption^{2,19}

FGF23 in patients with XLH^{3,17,20,21}



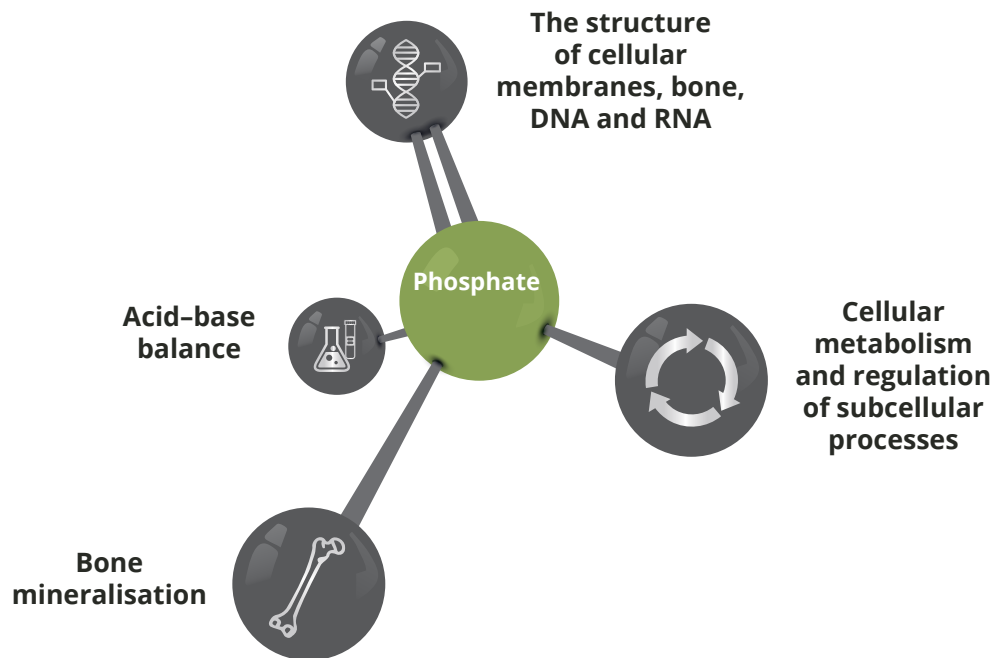
- Excess FGF23 signalling leads to:^{2,19}
 - Renal phosphate wasting
 - Suppressed circulating 1,25(OH)₂D, reducing intestinal phosphate reabsorption
- The resulting chronic hypophosphataemia leads to reduced bone mineralisation and rickets/osteomalacia³

Legend



*Both 1,25(OH)₂D and 25(OH)D are 24-hydroxylated, however 1,25(OH)₂D is the preferred substrate
 1,25(OH)₂D, 1,25-dihydroxyvitamin D; FGF23, fibroblast growth factor 23; PHEX, phosphate-regulating neutral endopeptidase, X-linked;
 TRP, tubular reabsorption of phosphate; XLH, X-linked hypophosphataemia

Phosphate homeostasis is critical for wellbeing and essential for a wide variety of key biological processes:¹⁶



- Phosphate requirements change with age and physiological need²²
- Phosphate homeostasis is highly regulated by 1,25(OH)₂D, PTH and FGF23²³

Clinical presentation²⁴⁻²⁸

Patients can present with a wide spectrum of disease manifestations

XLH is associated with considerable morbidity and reduced quality of life

Paediatric patients	Paediatric and adult patients	Adult patients
Rickets Delayed growth Craniosynostosis	Short stature Disproportionate growth Lower extremity deformity Tooth abscesses Osteomalacia Bone pain Joint pain and stiffness Muscle pain Muscle weakness Chiari malformation	Pseudofractures Osteoarthritis Extraosseus calcifications including: <ul style="list-style-type: none"> • Osteophytes • Enthesopathy • Spinal stenosis Hearing loss

Functional limitations and quality of life

Paediatric patients	Paediatric and adult patients	Adult patients
Delayed walking	Gait abnormalities Walking device use Diminished quality of life including psychosocial impact	Disability that impacts ability to work

RED FLAG SIGNS AND SYMPTOMS OF X-LINKED HYPOPHOSPHATAEMIA (XLH) IN PAEDIATRIC PATIENTS

If you see a newborn or infant with a **family history** of rickets or a phosphate wasting disorder, consider referral. Other red flags for XLH include:



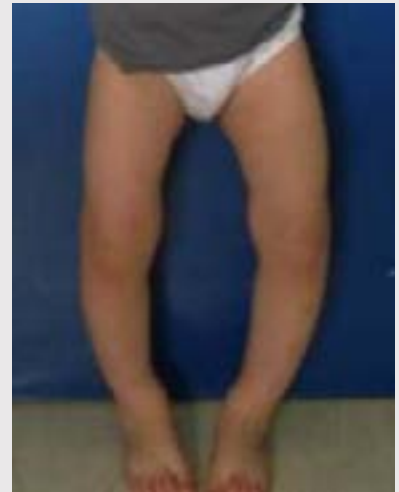1. BOWING IN LOWER LIMBS

XLH can impair healthy bone mineralisation, leading to rickets and progressive lower limb deformities in children.^{3,13,29} Bowing deformities of the leg typically present during the second year of life,^{3,13,29} however, appropriate treatment can improve mobility and growth outcomes.³⁰

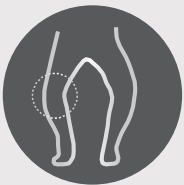

2. DELAYED WALKING WITH A WADDLING GAIT

XLH can impact motor development and mobility.^{13,31} During the second year of life, children with XLH typically present with delayed walking and an abnormal, or 'waddling' gait.^{13,31}



Genu Varum in a patient with XLH³²



3. PAIN IN LEGS

Bone, joint and muscle pain are highly prevalent in children with XLH and frequently affect the lower limbs.³¹



4. SHORT STATURE

In XLH, impaired limb growth with relatively preserved trunk growth results in disproportionate short stature. Decreased growth velocity is one of the main clinical symptoms of XLH.¹³



5. ABNORMAL HEAD SHAPE

Craniosynostosis is a condition associated with XLH in which one or more of the fibrous sutures in a very young skull prematurely fuses by turning into bone.¹³ This may lead to an abnormal head shape in children.

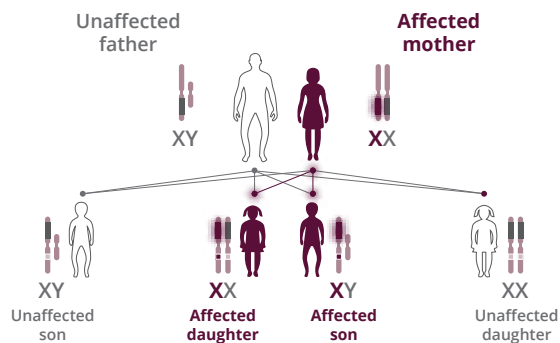
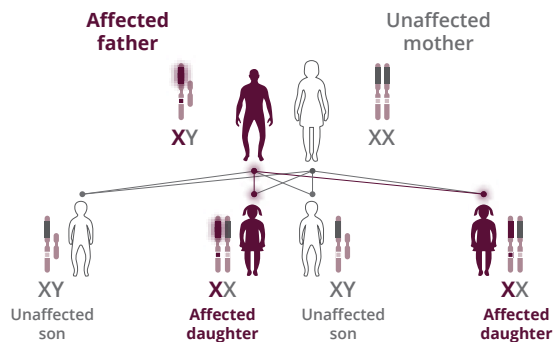


6. DENTAL ABSCESSSES

Dental features of XLH include spontaneous dental abscesses that occur in the absence of trauma or dental caries.³³ Impaired dentin mineralisation associated with XLH may contribute to subsequent bacterial penetration and consequent dental abscess despite the absence of carious lesions.³⁴

IN THE PRESENCE OF RED FLAG SIGNS OR SYMPTOMS, THE FOLLOWING INVESTIGATIONS AND ASSESSMENTS CAN HELP CONFIRM A DIAGNOSIS OF XLH

Inheritance pattern



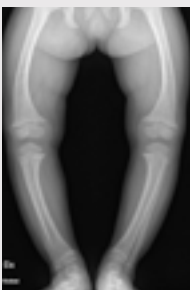FAMILY HISTORY¹³

- A positive family history can help confirm a diagnosis of XLH
- Any first-generation family member of a patient with XLH should be investigated for XLH; sons of males are not affected
- Mutational analysis of the *PHEX* gene can help in cases with a negative family history

PHYSICAL EXAMINATION

- A detailed clinical evaluation should include evidence of:¹³
 - Rickets
 - Growth failure
 - Dental abnormalities
 - Craniosynostosis

RADIOLOGICAL EXAMINATION



RED FLAG FINDINGS

- Rickets characterised by cupped and flared metaphyses and widened and irregular physes (growth plates) of the long bones^{3,13}
- Consider performing radiography of the knees and/or wrists and/or ankles to confirm a diagnosis of rickets¹³

Clinical photos are courtesy of Prof. Natascia Di Iorgi, IRCCS Istituto Giannina Gaslini (Italy)
Legs of a paediatric patient with XLH¹³

BIOCHEMICAL MEASURES

Selected biochemical characteristics of nutritional rickets and XLH¹³

Measure	Nutritional rickets	XLH
Serum Calcium	N, ↓	N
Serum Phosphate	N, ↓	↓
Urinary Phosphate	Varies	↑
ALP	↑↑↑	↑(↑↑)
25(OH)D	↓↓, N	N

N, normal; ↓, decreased; ↓↓ markedly decreased; ↑, elevated; ↑(↑↑), might range widely; ↑↑ or ↑↑↑, very elevated.

PEOPLE WITH XLH SHOULD BE URGENTLY REFERRED, DIAGNOSED AND TREATED

Prompt referral, diagnosis and early treatment. Early treatment of XLH is associated with superior clinical outcomes¹³

Care for patients with XLH should be provided by multidisciplinary teams^{13,35}

People with XLH may be treated with symptomatic or corrective treatments^{24,36}

REFERENCES:

1. Beck-Nielsen SS, et al. *Eur J Endocrinol.* 2009;160:491-97;
2. Martin A & Quarles LD. *Adv Exp Med Biol.* 2012;728:65-83;
3. Carpenter TO, et al. *J Bone Miner Res.* 2011;26:1381-88;
4. Che H, et al. *Eur J Endocrinol.* 2016;174:325-33;
5. Burnett CH, et al. *Am J Med.* 1964;36:222-32;
6. Rafaelsen S, et al. *Eur J Endocrinol.* 2015;174:125-36;
7. Gaucher C, et al. *Hum Genet.* 2009;125:401-11;
8. Mumm S, et al. *J Bone Miner Res.* 2015;30:137-43;
9. Whyte MP, et al. *J Clin Endocrinol Metab.* 1996;81:4075-80;
10. Rajah J, et al. *Eur J Pediatr.* 2011;170:1089-96;
11. Dixon PH, et al. *J Clin Endocrinol Metab.* 1998;83:3615-23;
12. Lo SH, et al. *Qual Life Res.* 2020;29:1883-93;
13. Haffner D, et al. *Nat Rev Nephrol.* 2019;15:435-55;
14. Kurosu H, et al. *J Biol Chem.* 2006;281:6120-3;
15. Andrukhova O, et al. *Bone.* 2012;51:621-8;
16. Penido MG, Alon US. *Pediatr Nephrol.* 2012;27:2039-48;
17. Christakos S, et al. *Physiol Rev.* 2016;96:365-408;
18. Bikle DD. *Chem Biol.* 2014;21:319-29;
19. Kinoshita Y, Fukumoto S. *Endocr Rev.* 2018;39:274-91;
20. Huang X, et al. *Bone Res.* 2013;2:120-32;
21. Quarles LD. *J Clin Invest.* 2008;118:3820-8;
22. Pettifor JM. *Eur J Pediatr.* 2008;167:493-9;
23. Bacchetta J, et al. *Metabolism.* 2020;103S:153865;
24. Dahir K, et al. *J Endocr Soc.* 2020;4(12):bvaa141;
25. Linglart A, et al. *Endocr Connect.* 2014;3:R13-R30;
26. Linglart A, et al. *ICCBH 2015.* Poster P198;
27. Haffner D, et al. *Pediatrics.* 2004;113:e593-6;
28. Veilleux LN, et al. *J Clin Endocrinol Metab.* 2012;97:E1492;
29. Beck-Nielsen SS, et al. *Orphanet J Rare Dis.* 2019;14(1):58;
30. Imel EA, et al. *Lancet.* 2019;393:2416-27;
31. Skrinar A, et al. *J Endocr Soc.* 2019;3:1321-1334;
32. Gizard A, et al. *Endocr Connect.* 2017;6(8):566-573;
33. Lee BN, et al. *Restor Dent Endod.* 2017;42(2):146-151;
34. Chaussain-Miller C, et al. *Oral Dis.* 2007;13(5):482-9;
35. Raimann A, et al. *Wien Med Wochenschr.* 2020;170:116-3;
36. Seefried L, et al. *Osteoporos Int.* 2021;32:7-22.